

Case Report

Varicella-Zoster Virus Infection and Brivudine Therapy: Unexpected Response in Sarcoma Patient

 Osman Köstek,  Murat Sarı,  İbrahim Vedat Bayoğlu

Department of Medical Oncology, Marmara University, Faculty of Medicine, İstanbul, Turkey

Abstract

Soft tissue sarcoma is a heterogeneous disease and treatment options are limited in advanced stage settings. Brivudine is a thymidine-nucleoside analog and inhibits DNA polymerase in VZV infection. We demonstrated a case of a patient who was diagnosed with both VZV infection and advanced stage sarcoma, and unexpected anti-tumoral response after brivudine therapy.

Keywords: VZV-infection, brivudine, undifferentiated pleomorphic sarcoma, anti-tumoral response

Cite This Article: Köstek O, Sarı M, Bayoğlu İV. Varicella-Zoster Virus Infection and Brivudine Therapy: Unexpected Response in Sarcoma Patient. *EJMO* 2022;6(2):182–185.

Soft tissue sarcoma (STS) is a rare and heterogeneous disease of cancer cells that originated from mesenchymal parenchyma and accounts for about 1% of all adult malignancies.^[1] Adult STS patients have the disease subtypes as STS of superficial/trunk, extremities or head and neck, retroperitoneal or intrabdominal STS, aggressive fibromatoses, and rhabdomyosarcoma. Surgical resection is the main primary treatment for the resectable disease. In advanced or metastatic disease systemic therapy is needed to control disease spread. Unfortunately, therapeutic options are limited against STS, although anthracycline and gemcitabine-based chemotherapy options and targeted therapies have promising results in certain histologies.^[2, 3] Undifferentiated pleomorphic sarcoma (UPS) is an invasive disease as “tumors of uncertain differentiation” of STS histologies. Systemic treatment of metastatic UPS is as same as other STS histologies and treatment options are very limited.

Brivudine is a thymidine-nucleoside analog and causes DNA damage by inhibiting DNA polymerase in VZV infection, by acting as an alternative substrate to deoxy-

thymidine triphosphate, causing viral DNA strand breakage.^[4] As far as we know, no case has been reported regarding brivudine and cytotoxicity against any solid cancer types.

On the other hand, attenuated poliovirus (PVSRIPO) injection to recurrent GBM lesions improved overall survival in phase I clinical trial.^[5] It was thought that viral infection of cancer patients may result in different clinical outcomes and may lead to a change in T cell activation against tumor microenvironment and cancer cells.

Herein, we present a case of a patient with newly-diagnosed both undifferentiated pleomorphic sarcoma and VZV infection and received brivudine and surprisingly and unexpectedly remarkable response to sarcoma lesions.

Case Report

An 81-year-old male patient was diagnosed with undifferentiated pleomorphic sarcoma of the lesion located left upper chest wall and bilateral pleural metastasis. Laboratory findings were within normal limits. Physical examination re-

Address for correspondence: Osman Köstek, MD. Marmara Üniversitesi Tıp Fakültesi Tıbbi Onkoloji Anabilim Dalı, İstanbul, Turkey

Phone: +90 554 585 73 90 **E-mail:** osmankostek@hotmail.com

Submitted Date: February 01, 2022 **Accepted Date:** May 09, 2022 **Available Online Date:** June 06, 2022

©Copyright 2022 by Eurasian Journal of Medicine and Oncology - Available online at www.ejmo.org

OPEN ACCESS This work is licensed under a Creative Commons Attribution-NonCommercial 4.0 International License.



vealed about 1 cm solid mass on the right anterior chest wall and about 2,5 cm mass on periumbilical region. On the other hand, he suffered from zona lesions located on the right neck and chest wall including a mass lesion. Biopsy was consulted to our soft tissue sarcoma experienced pathologist and confirmed it as undifferentiated pleomorphic sarcoma. In order to stage the disease, CT imagings were ordered.

Figure 1 shows initial thorax tomography which demonstrates mass on the left anterior chest wall and pleural metastasis on bilateral locations. The patient was consulted to the medical oncology department and admitted to us 2 weeks later, his PET/CT imaging demonstrated disease progression (Fig. 1). Then, the patient had VZV – zona –infection and consulted to dermatology. He received brivudine for VZV infection. We advised the patient to admit to oncology outpatient after VZV infection therapy. After 4 weeks, surprisingly, a remarkable response to brivudine was inspected through physical examination, and thorax and abdomen CT imagings showed a nearly completed response (Fig. 2 a and 2b). We did not give any chemotherapy or cytotoxic agent against UPS lesions.

We advised only monitoring with active follow-up. Unfortunately, he did not continue to follow up later. After 27 months, his last visit was due to pneumonia, and died in the intensive care unit. The last thorax CT imaging showed disease recurrences on bilateral pleural surfaces (Fig. 3).

Discussion

We report the case of a patient with newly-diagnosed both UPS and a VZV infection, who was treated with brivudine and had a remarkable and unexpected objective response of tumoral lesions to brivudine therapy.

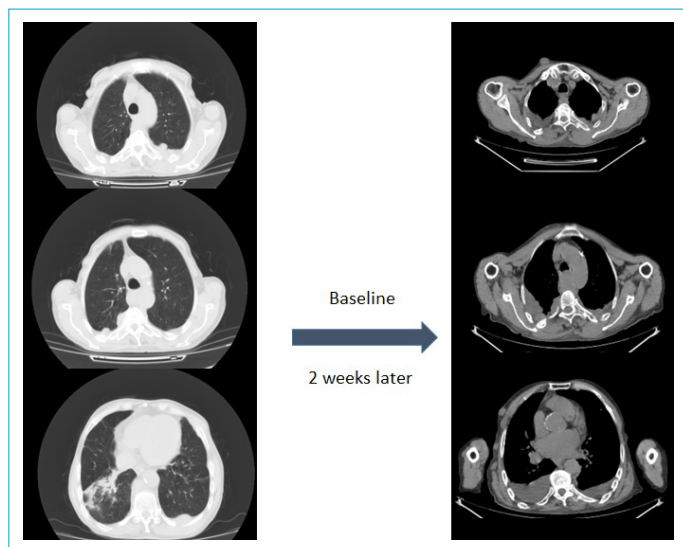


Figure 1. Baseline and 2 weeks later thorax CT imaging of progressive disease.

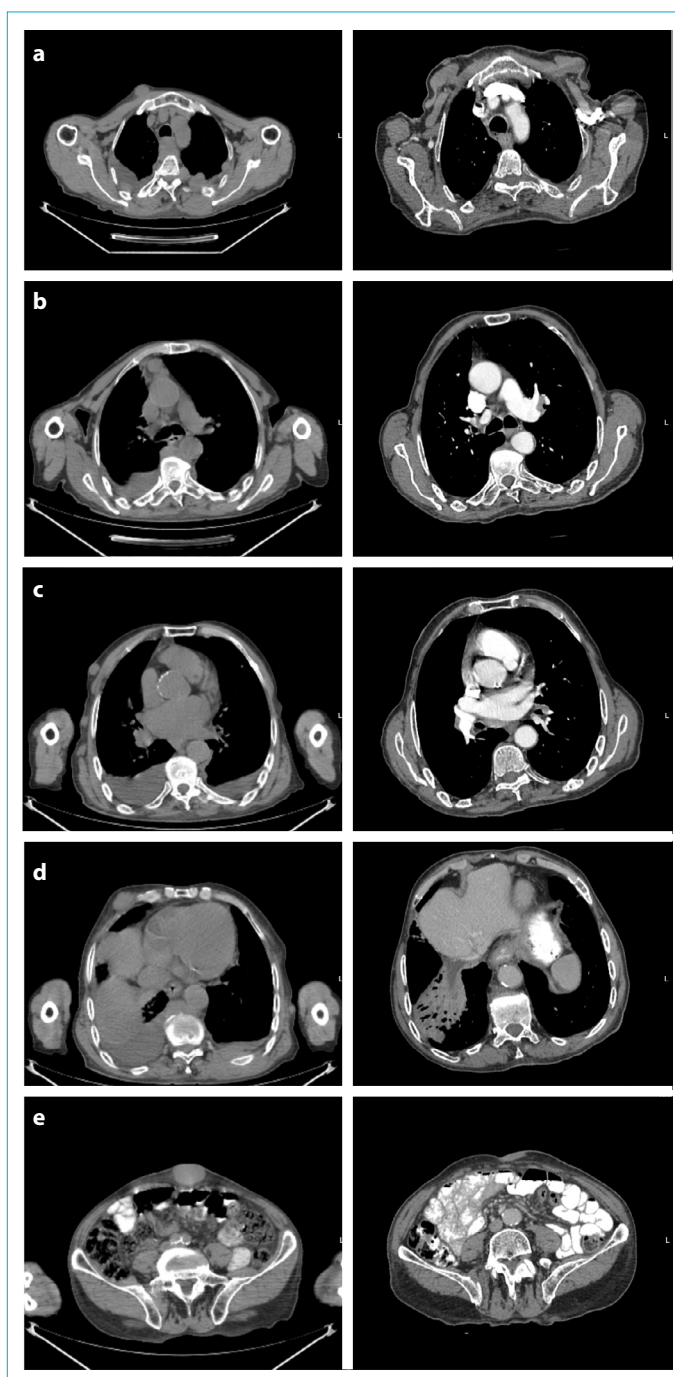


Figure 2. Change in tumoral lesions after VZV infection and brivudine therapy.

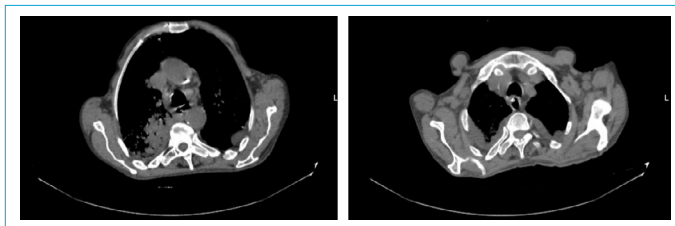


Figure 3. Thorax CT image of the patient in the intensive care unit shows disease recurrence.

Nucleoside analogs are used in the treatment of viral infections or cancer. Inhibition of DNA replication by depleting deoxyribonucleotide synthesis leads to cell growth arrest or cell death. For instance, inhibition of thymidylate synthase and ribonucleotide reductase impairs DNA replication by structurally modified nucleoside analogs are used in the treatment of cancer cells.^[6] On the other hand, thymidine kinase is a DNA salvage enzyme and play role in regenerating thymidine for DNA synthesis.^[7] Apart from DNA synthesis, it has a critical role in the repair mechanisms after DNA damage.^[8] In addition, it was shown that serum human TK activity may differ between solid cancer cells regarding breast and prostate cancer cells.^[9, 10] There is an important question about whether human TK is different than viral (herpes) TK. Although there is limited data, human TK was found to be molecularly different than viral TK. Further studies are needed to discover these molecular differences may be an option for cancer treatment.^[7, 11, 12] Moreover, there is new data about serum thymidine kinase levels are above in patients with soft tissue sarcoma and there is not enough data on the importance of TK activity and sarcoma pathogenesis.^[13] Current studies are now trying to identify links between TK1 and cancer pathogenesis.^[7] In addition, brivudine is an oral thymidine nucleoside analog and has greater activity against viral TK and its activity against tumor cells is unknown. Brivudine (RP101) as a potential cancer drug was shown a novel approach for the prevention of chemotherapy resistance and enhancement of chemosensitivity in animals and pancreatic cancer patients.^[14] But later, there was no further studies in the field of oncology. Herein, we firstly demonstrated that patients with UPS who received brivudine had surprisingly near-complete responses to brivudine about 4-weeks later (Fig. 2). Further studies about brivudine and its potential role against soft tissue sarcoma are needed.

On the other hand, in the growth of cancer tissue, the tumor microenvironment establishes acquired MHC and antigen loss to escape from the immune system. By different mechanisms including viral infection, this pathway may reverse and lead to a tumor microenvironment immune flare status-from cold status to hot- and may enhance the tumor antigen-specific T cell activation and recruitment. In 2018, a poliovirus monotherapy for recurrent glioblastoma improved long-term survival, and later, LUMINOS-101 phase II (NCT04479241) trial is designed to investigate whether pembrolizumab plus poliovirus therapy in patients with recurrent GMB will improve survival or not.^[5, 15] In our patient who was infected with VZV during diagnosis procedure and zona, dermatome was on a mass lesion at the right upper chest wall and it was thought whether his tumor microenvironment gained tumor antigen-specific T cell ac-

tivation and recruitment is another theory of this clinical scenario. We have started to investigate the possible efficacy or therapeutic potential of brivudine on fibrosarcoma cell culture. If it is demonstrated, possible pathways related to anti-neoplastic efficacy will be explained with further studies including transcriptome analysis.

Further studies are needed to clarify this surprising response to UPS lesions and whether this response belongs to brivudine or VZV infection-mediated T cell activation against tumor cells. Due to fact the limited therapeutic agents against soft tissue sarcoma, it will be valuable to demonstrate the potential efficacy of nucleoside analog or a potential oncolytic viral therapy agent against soft tissue sarcoma.

Disclosures

Peer-review: Externally peer-reviewed.

Conflict of Interest: The authors declare that there is no conflict of interest that could be perceived as prejudicing the impartiality of the present study. The present study did not receive any funding.

Authorship Contributions: Concept – O.K.; Design – O.K., İ.V.B.; Supervision – M.S, İ.V.B.; Literature search – O.K., M.S.; Writing – O.K., M.S.; Critical review – M.S., İ.V.B.

References

1. Siegel RL, Miller KD, Fuchs HE, Jemal A. Cancer statistics, 2022. *CA Cancer J Clin* 2022;72:7–33. [\[CrossRef\]](#)
2. Bramwell VH, Anderson D, Charette ML. Doxorubicin-based chemotherapy for the palliative treatment of adult patients with locally advanced or metastatic soft tissue sarcoma. *Cochrane Database Syst Rev* 2003;2003:Cd003293. [\[CrossRef\]](#)
3. Young RJ, Natukunda A, Litière S, Woll PJ, Wardelmann E, van der Graaf WT. First-line anthracycline-based chemotherapy for angiosarcoma and other soft tissue sarcoma subtypes: pooled analysis of eleven European Organisation for Research and Treatment of Cancer Soft Tissue and Bone Sarcoma Group trials. *Eur J Cancer* 2014;50:3178–86. [\[CrossRef\]](#)
4. Keam SJ, Chapman TM, Figgitt DP. Brivudin (bromovinyl deoxyuridine). *Drugs* 2004;64:2091–7; discussion 8–9. [\[CrossRef\]](#)
5. Desjardins A, Gromeier M, Herndon JE 2nd, Beaubier N, Bolognesi DP, Friedman AH, et al. Recurrent glioblastoma treated with recombinant poliovirus. *N Engl J Med* 2018;379:150–61.
6. Van Rompay AR, Johansson M, Karlsson A. Substrate specificity and phosphorylation of antiviral and anticancer nucleoside analogues by human deoxyribonucleoside kinases and ribonucleoside kinases. *Pharmacol Ther* 2003;100:119–39.
7. Bitter EE, Townsend MH, Erickson R, Allen C, O'Neill KL. Thymidine kinase 1 through the ages: a comprehensive review. *Cell Biosci* 2020;10:138. [\[CrossRef\]](#)
8. Chen YL, Eriksson S, Chang ZF. Regulation and functional contribution of thymidine kinase 1 in repair of DNA damage. *J Biol Chem* 2010;285:27327–35. [\[CrossRef\]](#)

9. Jagarlamudi KK, Hansson LO, Eriksson S. Breast and prostate cancer patients differ significantly in their serum Thymidine kinase 1 (TK1) specific activities compared with those hematological malignancies and blood donors: implications of using serum TK1 as a biomarker. *BMC Cancer* 2015;15:66.
10. Jagarlamudi KK, Shaw M. Thymidine kinase 1 as a tumor biomarker: technical advances offer new potential to an old biomarker. *Biomark Med* 2018;12:1035–48. [\[CrossRef\]](#)
11. Munch-Petersen B, Tyrsted G. Thymidine kinase isoenzymes in human acute monocytic leukemia. *Mol Cell Biochem* 1985;66:185–91. [\[CrossRef\]](#)
12. Gentry GA. Viral thymidine kinases and their relatives. *Pharmacol Ther* 1992;54:319–55. [\[CrossRef\]](#)
13. Jaamaa S, Nevala R, Jagarlamudi K, Tukiainen E, Blomqvist C, Sampo M. Serum concentration of thymidine kinase 1 (TK1) as a tumor marker in soft tissue sarcomas. *Anticancer Res* 2022;42:1509–15. [\[CrossRef\]](#)
14. Heinrich JC, Tuukkanen A, Schroeder M, Fahrigh T, Fahrigh R. RP101 (brivudine) binds to heat shock protein HSP27 (HSPB1) and enhances survival in animals and pancreatic cancer patients. *J Cancer Res Clin Oncol* 2011;137:1349–61. [\[CrossRef\]](#)
15. Sloan AE, Buerki RA, Murphy C, Kelly AT, Ambady P, Brown M, et al. LUMINOS-101: Phase 2 study of PVSRIPO with pembrolizumab in recurrent glioblastoma. *J Clin Oncol* 2021;39:TPS2065. [\[CrossRef\]](#)